

**Crusted Scabies in Poorly Managed HIV Infected Patient at Tanga Regional Referral
Hospital, Tanzania**

Lucheri E. kweka^{1, 2*}, Juliah W. Muchunu^{1, 2}, Shabiri W. Moizal², Zalha Nuhu² Jumanne Karia^{1, 2}

¹Tanga College of Health and Allied Sciences, Tanga, Tanzania

²Tanga Regional Referral Hospital, Tanga, Tanzania

***Corresponding author:**

Lucheri Kweka

Tanga College of Health and Allied Sciences

P. O. Box 5030

Tanga, Tanzania

Email: kweka76@gmail.com

OPEN ACCESS JOURNAL**Abstract**

Severe immune suppression especially due to human immunodeficiency virus (HIV) infection, is a risk factor for crusted scabies. We report a case of 33-year-old man with poorly managed HIV infection who presented with four months' history of scaly itching skin rashes which initially started on the wrist, elbow, buttocks, finger and toes webs, and thigh and later progressed to involve the whole body. As time went by the scales thickened and due to scratching led to mild bleeding over the skin and became infected with bacteria.

Physical examination revealed generalized hyperkeratotic whitish brownish scales with excoriations, yellowish crusts indicating bacterial superinfection. Skin scrapings soaked in 10% of potassium hydroxide preparation examined under microscope revealed scabies mites. The patient was treated with oral ivermectin 12mg on day one then repeated on day 7 and 14 together with lindane lotion 1% applied at night on day 1, 7 and 14. He performed daily soaking with wet gauze of 0.1% potassium permanganate solution to treat local bacterial infection and application of vaseline petroleum gel mixed with glycerin. He was discharged on day 18th in very good condition after sessions of adherence counselling and restarted on antiretroviral drugs (ARVs).

Key Words: *Crusted scabies, Severe immune suppression.*

Introduction

Scabies is highly contagious and intensely pruritic debilitating parasitic dermatoses caused by *Sarcoptes scabiei* var. *hominis* (1). Scabies can affect any age group. However, it is more seen in children younger than 15 years and prisoners associated with overcrowding, poor sanitation and poor living condition. Its incidence has decreased in recent years due to ivermectin mass drug administration campaign in areas with neglected tropical diseases (lymphatic filariasis and onchocerciasis) (1, 2). Crusted scabies is rare but highly infectious due to high number of mites present in crusts, affecting mainly individuals with immune suppression due to various reasons including HIV infection (3, 4).

Patients with severe immune suppression are unable to mount strong immune response following infestation with scabies and therefore are prone to get generalized crusted skin lesions (5, 6). These crusts are more prominent over extremities and extensor surfaces and there is possibility of becoming infected with bacteria between the cracks (7). Diagnosis is mainly clinical though this may become challenging for clinicians with limited experience. Skin scrapings obtained from patients are soaked in 10% to 20% of potassium hydroxide preparation and examined under microscope to reveal adults mites or eggs (8).

We present a case of severe immune suppression due to HIV infection with crusted scabies.

Case presentation

A 33-year-old man diagnosed with HIV infection three years ago and started on ARVs of which he stopped in the past five months without clear reason presented at medical department with four months' history of scaly itching skin rashes which initially started on the wrist, elbow, buttocks, thigh, finger and toes webs later progressed to the whole body. As time went by the scales developed and due to scratching led to mild bleeding over the skin. The itching was more marked at night. The patient was initially treated twice during the course of this illness at nearby primary health facility with benzyl benzoate emulsion without improvement. He was a petty trader, living alone and had history of drinking local beer and cigarette smoking for approximately ten years but did not show signs of addiction during hospital stay. Physical examination revealed young man of poor personal hygiene with generalized hyperkeratotic whitish brownish scales with excoriations, yellowish crusts indicating bacterial superinfection all over the body sparing only face (Figure 1). The rest of physical examination was unremarkable. The CD4+ cell count was 18cell/uL and viral load 240,000 copies/uL. Skin scraping soaked in 10% of potassium hydroxide preparation and examined under microscope showed numerous scabies mites (Figure 2). The patient was

OPEN ACCESS JOURNAL

treated with oral ivermectin 12mg on day one and repeated on day 7 and 14 together with lindane lotion 1% applied at night on day 1, 7 and 14. He carried out daily soaking with 0.1% of potassium permanganate bath to treat the local bacterial infection and application of vaseline petroleum jelly since he could not get salicylic acid ointment to remove the scales. He was discharged on day 18th in very good condition (Figure 3) after sessions of adherence counselling and was restarted on ARVs, a combination of Dolutegravir, Lamivudine and Tenofovir disoproxil fumarate.

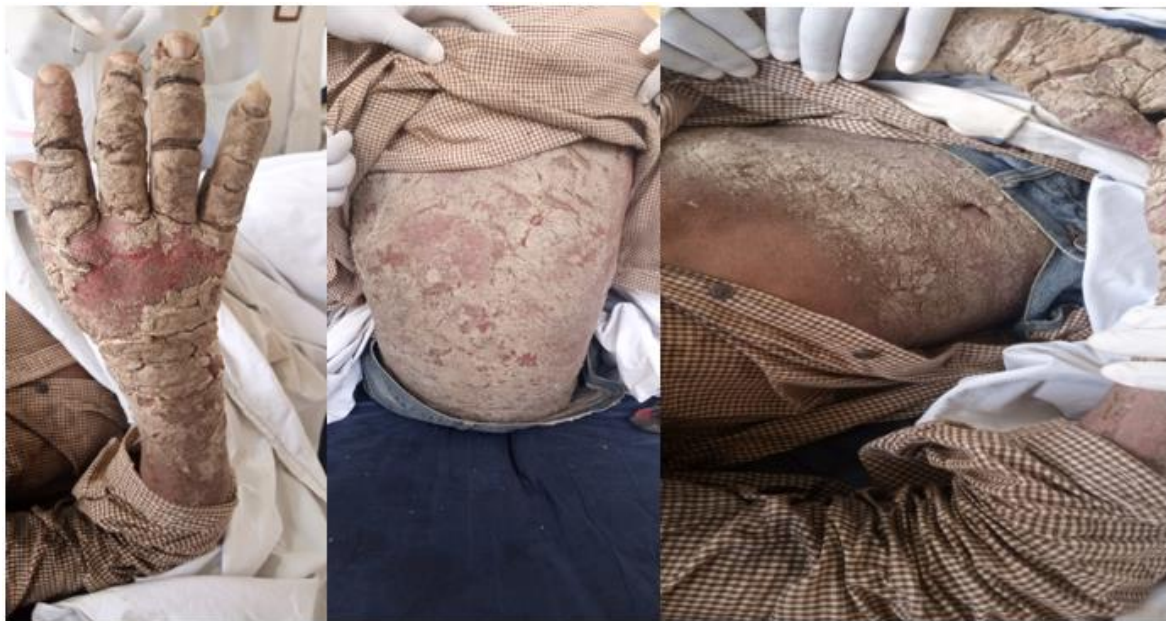

Figure 1. Thick, hyperkeratotic and crusting lesions distributed extensively over the limbs, abdomen and back in 33-year-old man with poorly controlled HIV infection before treatment

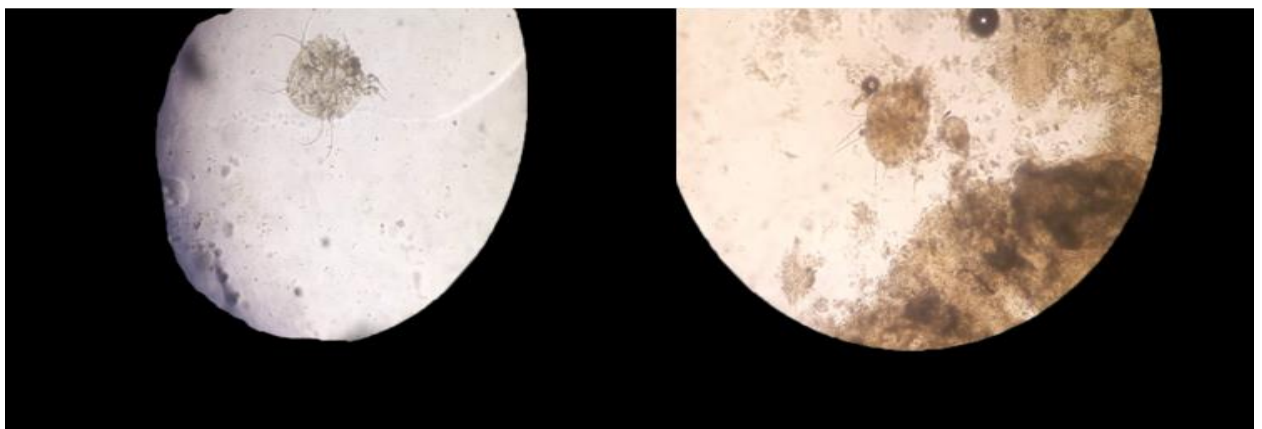


Figure 2. Skin craping of the patient examined under microscope revealed scabies mites

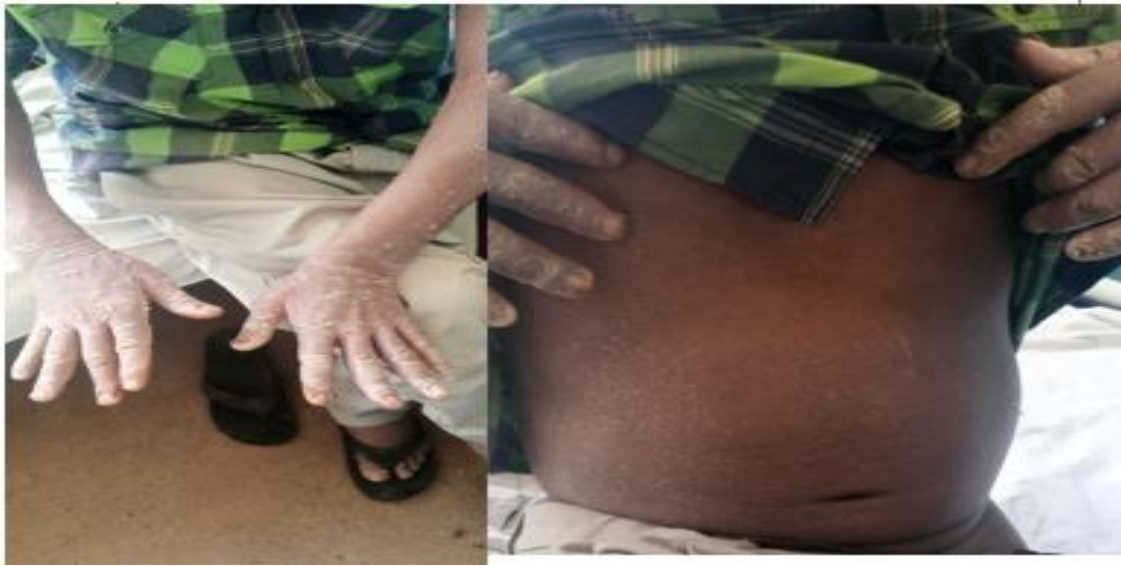

Figure 3. Patient with crusted scabies 18 days after initiation of treatment

Discussion

It is generally known that individuals with immune suppression, for example those with HIV infection, malignancy and those who are receiving immunosuppressive treatment are prone to crusted form of scabies due to inability to mount itch reflex and failure of the body to mount enough immune response against the infection (3, 5, 9). Diagnosis of scabies is made clinically and confirmation is done through skin scrapings soaked in preparation of 10% to 20% potassium hydroxide and examined under microcopy which will show either adult mites or eggs (10). For crusted scabies, a combination therapy of ivermectin given for a minimum of two doses; day one and day fourteen together with topical benzyl benzoate solution provides optimal success rate than use of monotherapy (11, 12, 13). Potassium permanganate solution 0.1% is effective in treatment of local bacterial and fungal infection(14, 15). Though crusted scabies is highly infectious and infection to health workers and other patients has been reported in other cases (10, 16, 17), there was no reported infection to health workers or other patients secondary to this case as he was isolated and personal protective equipment were used during his care.

Conclusion

This case report highlights the importance of controlling HIV replication by the use of antiretroviral drugs and hence restoring immune function to prevent debilitating form of crusted scabies infestation.

OPEN ACCESS JOURNAL**Ethical considerations and consent to publish**

Ethical clearance to publish this case report was obtained from the patient and Tanga Regional Referral hospital.

Competing interests

There are no competing interests.

Authors' contributions

LEK contributed in the management of the patient and writing the manuscript, JWM and SM contributed to management of the patient. ZN and JK revised the manuscript. All authors read and approved the final manuscript.

References

1. Widaty S, Miranda E, Cornain EF, Rizky LA. Scabies: update on treatment and efforts for prevention and control in highly endemic settings. *J Infect Dev Ctries*. 2022 Feb 28;16(2):244-251.
2. Anderson KL, Strowd LC. Epidemiology, diagnosis, and treatment of scabies in a dermatology office. *J Am Board Fam Med*. 2017 Jan 2;30(1):78-84.
3. Roberts LJ, Huffam SE, Walton SF, Currie BJ. Crusted scabies: Clinical and immunological findings in seventy-eight patients and a review of the literature. *J Infect*. 2005 Jun;50(5):375-81.
4. Hall JC, Brewer JH, Appl BA. Norwegian scabies in a patient with acquired immune deficiency syndrome. *Cutis*. 1989;43(4).
5. Paparizos V, Vasalou V, Velissariou E, Kourkounti S, Daskalakis E, Rigopoulos D. Norwegian scabies presenting as erythroderma in HIV: A case report. *Infez Med*. 2019;27(3).
6. Khat N, Kudligi C, Rathod RM, Kuntoji V, Bhagwat PV, Ramachandra ST, et al. A clinical study of mucocutaneous manifestation of HIV/AIDs and its correlation with CD4 count. *J Pakistan Assoc Dermatologists*. 2021;30(4).
7. Wendel K, Rompalo A. Scabies and pediculosis pubis: An update of treatment regimens and general review. *Clin Infect Dis*. 2002 Oct 15;35(Suppl 2):S146-51.
8. Chandler DJ, Fuller LC. A Review of Scabies: An Infestation More than Skin Deep. *Dermatology*. 2019;235(2):79-90.
9. Kosmala A, Szymoniak-Lipska M, Jałowska M, Dobrzyńska M, Bowszyc-Dmochowska M, Adamski Z, et al. Crusted scabies in a patient with systemic disorders - Evaluation of ivermectin treatment results. *Przegl Dermatol*. 2019;106(6).
10. Orkin M. Scabies in AIDS. Vol. 12, *Seminars in Dermatology*. 1993.
11. Alberici F, Pagani L, Ratti G, Viale P. Ivermectin alone or in combination with benzyl benzoate in the treatment of human immunodeficiency virus-associated scabies. *Br J Dermatol*. 2000 May;142(5):969-72.
12. Corbett EL, Crossley I, Holton J, Levell N, Miller RF, De Cock KM. Crusted ("Norwegian") scabies in a specialist HIV unit: Successful use of ivermectin and failure to prevent nosocomial transmission. *Genitourin Med*. 1996 Apr;72(2):115-7.
13. Sharma R, Singal A. Topical permethrin and oral ivermectin in the management of scabies: A prospective, randomized, double blind, controlled study. *Indian J Dermatol Venereol Leprol*. 2011;77(5).

OPEN ACCESS JOURNAL

14. Wahab SA, Taib T, Ridzwan R. The Efficacy of Super-oxidised Hydrogel and Solution Compared to Potassium Permanganate Dressing for the Management of Cellulitis. In 2021.
15. Anderson I. Should potassium permanganate be used in wound care? Nurs Times. 2003;99(31).
16. Guggisberg D, De Viragh PA, Constantin C, Panizzon RG. Norwegian scabies in a patient with acquired immunodeficiency syndrome. Dermatology. 1998;197(3):306-8.
17. Zafar AB, Beidas SO, Sylvester LK. Control of Transmission of Norwegian Scabies. Infect Control Hosp Epidemiol. 2002 May;23(5):278-9.